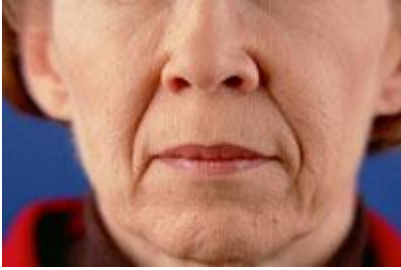
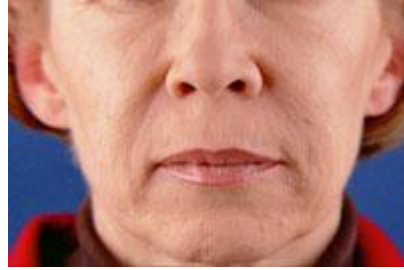
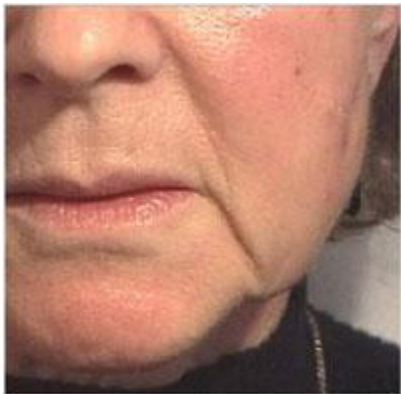Dermal Fillers Before and After Images



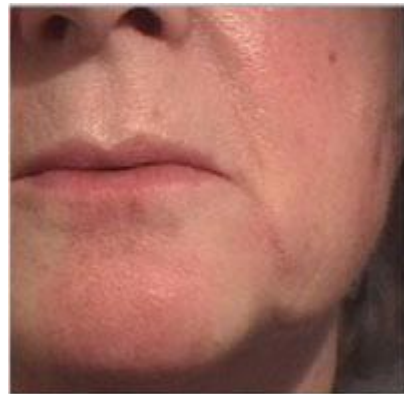Left picture: Nasolabial lines before



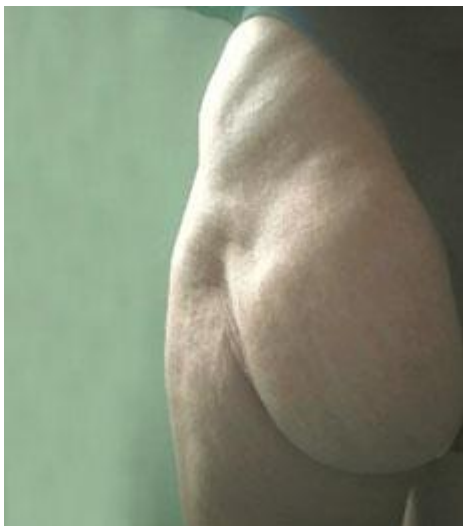Right picture: Nasolabial lines after



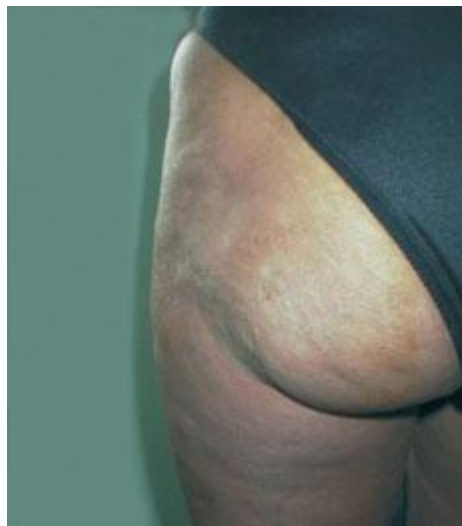Left picture: Nasolabial folds and oral commissures before



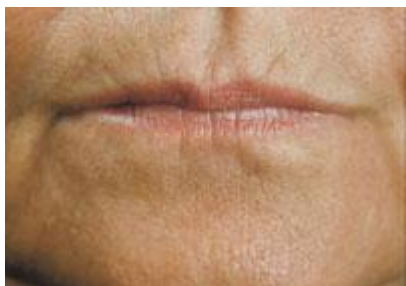Right picture: Nasolabial folds and oral commissures after



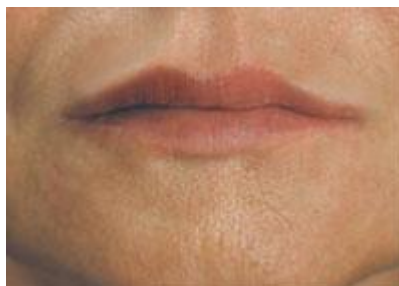Left picture: Posterior before



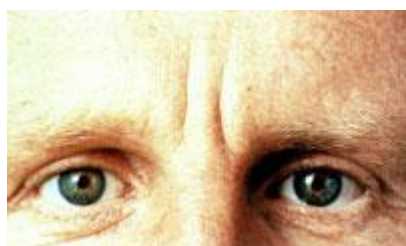Right picture: Posterior after injection.



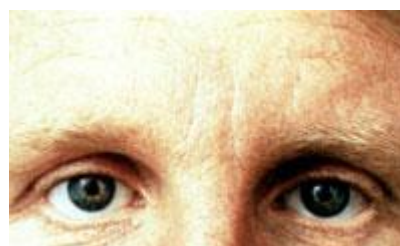Left picture: Thin lips and lip lines lines



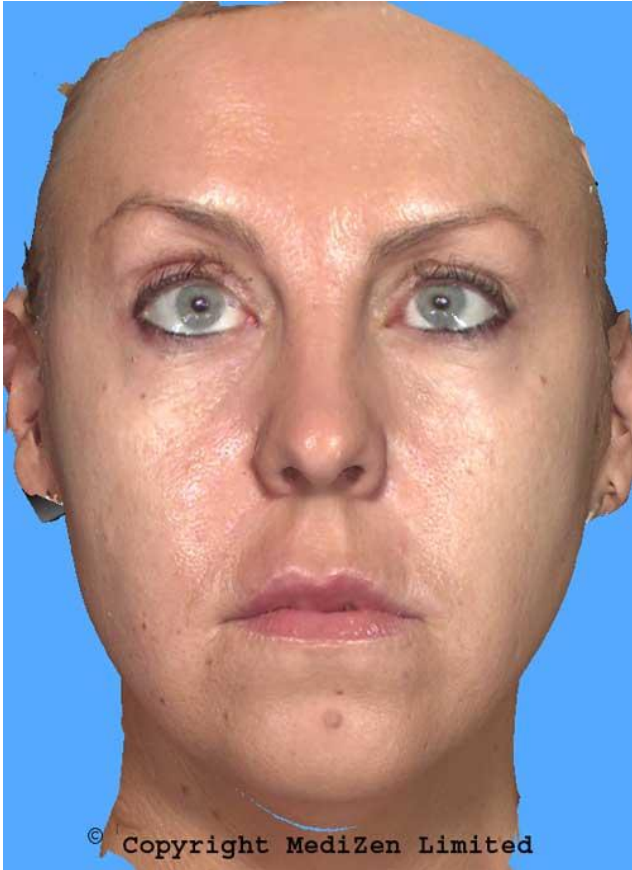Right picture: Improvement in lip shape and lip lines lines



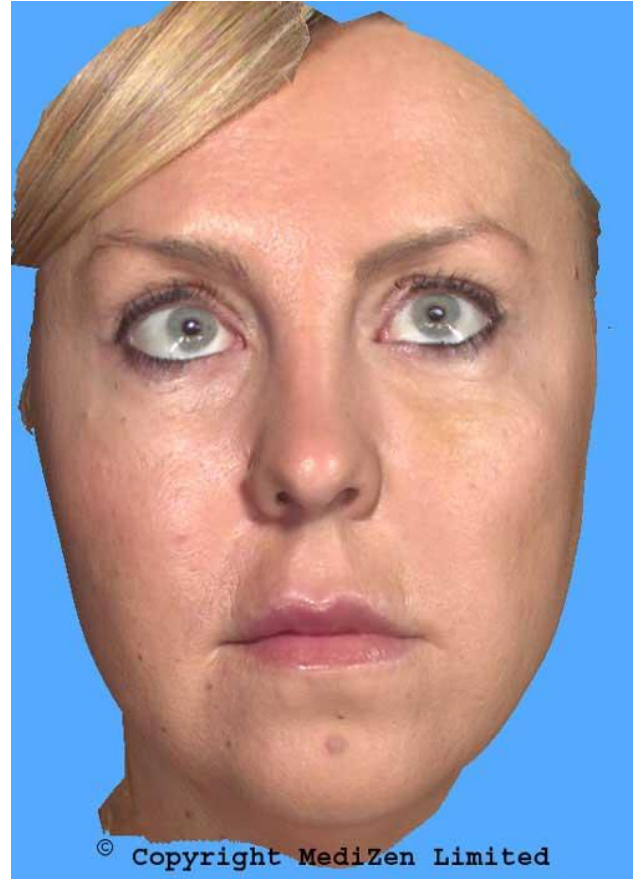
Left picture: Glabellar frown lines before



Right picture: Glabellar frown lines after

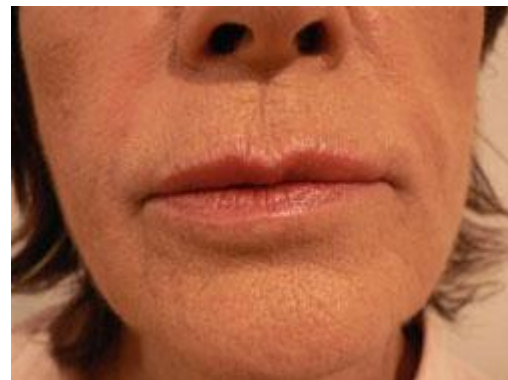
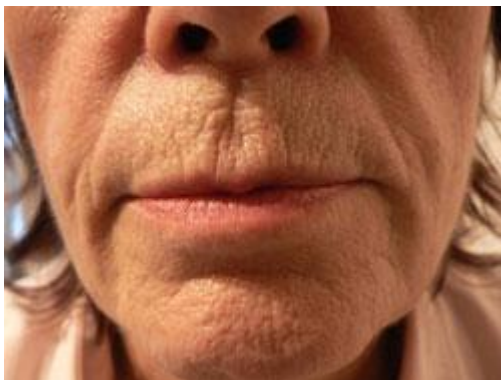
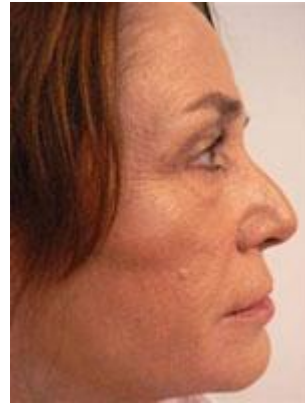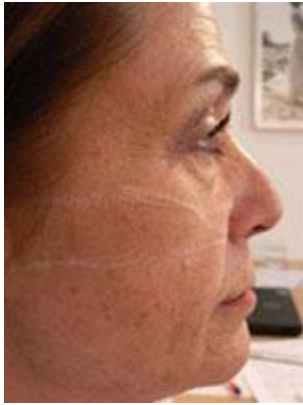Before Treatment



Subtle reshaping of the cheeks with [Restylane SubQ](#) (Images taken using [MediZen's](#) VECTRA 3D imaging system)

Images provided courtesy of Dr David Eccleston at [MediZen](#)





Left Images:

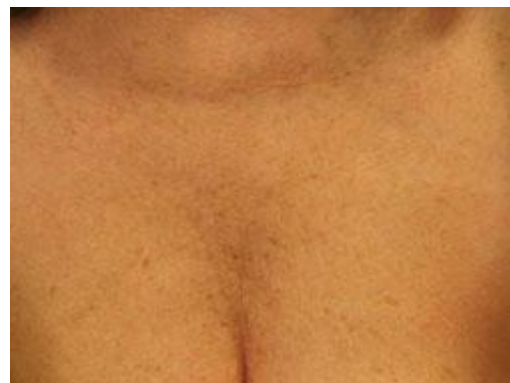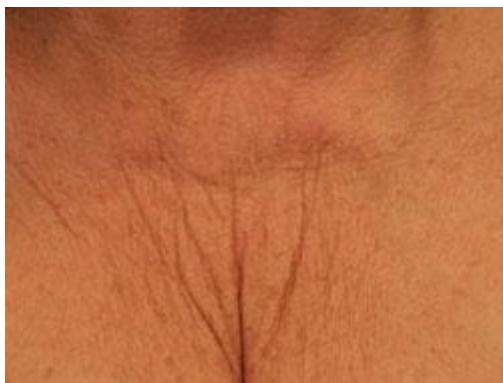Female, aged 60.

Peri-oral lines around the mouth and mid face volume loss before treatment.

Right images:

After peri-oral treatment and mid-face volumising with [Evolence™](#) Breeze, (plus combination Botox® treatment.)

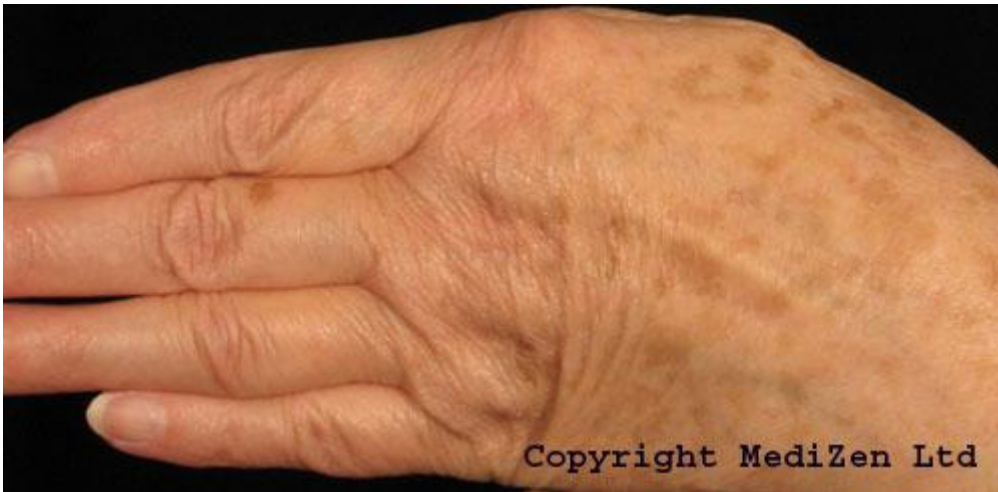Images provided courtesy of [Marea Brennan Thorns](#) RGN at MBNS Clinic.



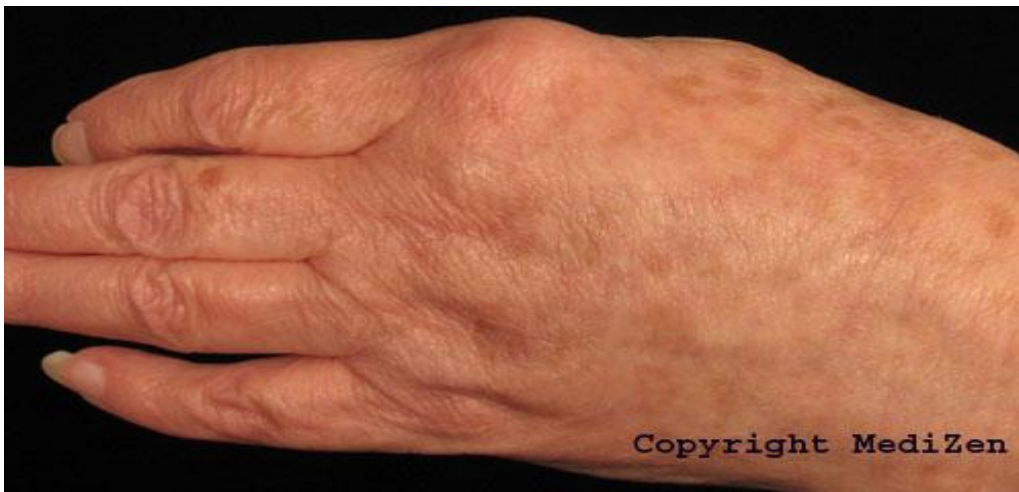Female, décolletage (area between neck and breasts) before treatment.

Female, décolletage 6 weeks post treatment with [Belotero®](#).

Images provided courtesy of Dr. Geoff Fairris, Dermatologist at the Wessex Skin Clinic.

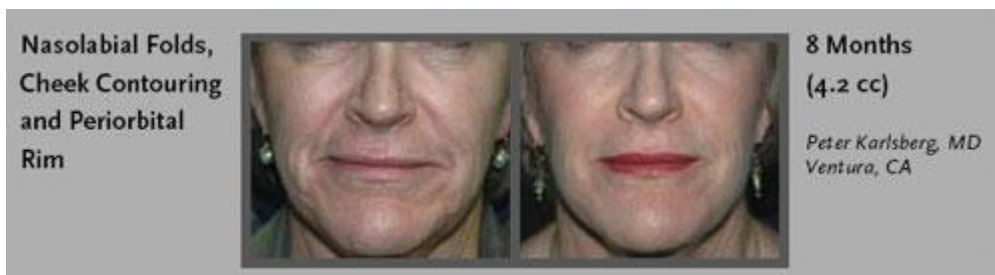

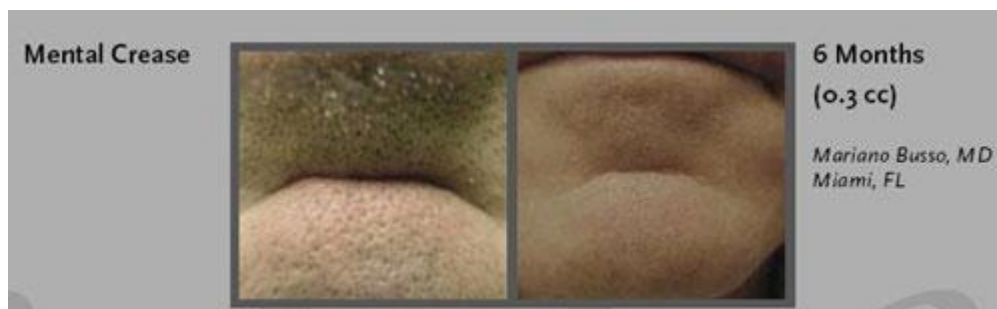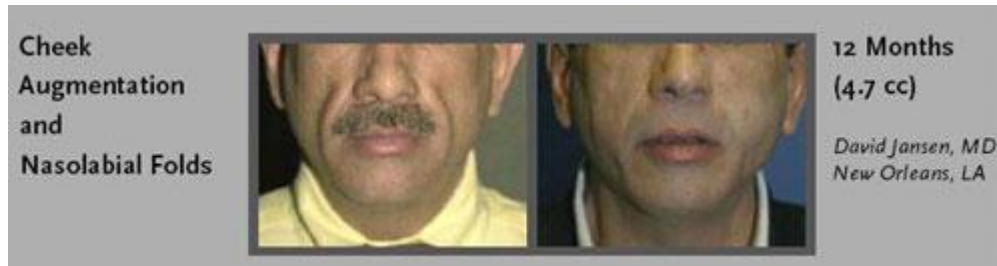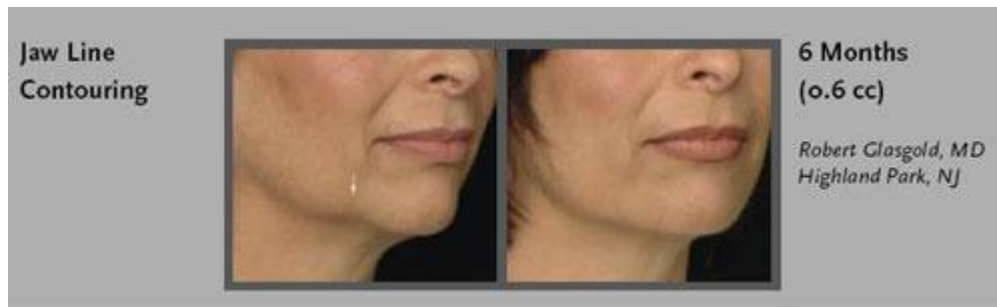Thin skin and loss of fat revealing veins and bones in the hand.



Improvement in appearance following treatment with [Radiesse](#).

Images provided courtesy of [MediZen Clinics Ltd](#)





Images provided: [BioForm](#) .

(All before and after photographs are real patients, your results may differ).